

ORIGINAL SCIENCE PRESENTATION

In Vivo Endoscopy of Septal Fibers Following Different Liposuction Techniques Reveals Varying Degrees of Traumatization

Afschin Fatemi, MD

Introduction: The removal of fat via liposuction requires disruption of adipose tissue and the intrinsic collagen-based septal fiber network that supports and protects the blood and nerve supply to adipose tissue. Using septal fiber preservation as a marker for the relative trauma of a given liposuction technique, we quantified and compared the number of intact septal fibers following various liposuction methods using in vivo endoscopy.

Materials and Methods: Pilot studies using endoscopic imaging and quantification were conducted in 3 study groups that included 52 abdominoplasty patients, 12 cadavers, and 32 liposuction patients. Liposuction techniques performed included laser-assisted (924/975-nm LAL), power-assisted (PAL), suction-assisted (SAL), ultrasound-assisted (UAL), and power water-assisted liposuction (WAL). Gross dissection and in vivo endoscopy were used to qualitatively and quantitatively evaluate septal fiber preservation.

Results: The highest numbers of intact septal fibers were observed following either 924/975-nm LAL or PAL. SAL treatments left, on average, two thirds the number left after LAL or PAL. UAL and WAL were the most damaging, leaving one half or one third the number of fibers seen after LAL or PAL, respectively. In addition, 924/975-nm LAL and PAL were associated with less skin necrosis and blood in the aspirate as compared with WAL. Microscopy studies revealed that the greatest adipocyte cell membrane disruption occurred following 924/975-nm LAL.

Conclusions: These findings demonstrate that 924/975-nm LAL and PAL were associated with the greatest preservation of septal fibers while UAL and WAL were the most damaging.

The 924-nm LAL was also the most effective technique for disrupting adipocyte cell membranes.

A wide range of technologies is available for aesthetic body sculpting, including nonsurgical devices that use low-frequency ultrasound, radiofrequency,¹ light energy,² or a combination of these,^{3,4} with or without mechanical manipulation.⁵ These sculpting methodologies are noninvasive but require multiple treatments and deliver relatively superficial or temporary outcomes at best.^{1,2,4,5}

While invasive and somewhat traumatic in nature, liposuction is the gold standard for aesthetic body contouring. Modern-day liposuction relies more heavily on the tumescent wet technique because of the potential for fatal anesthesia-related complications with general anesthesia.⁶ Local tumescent anesthesia reduces the overall trauma of liposuction through hydrodissection of adipose tissue and is associated with a decline in adverse events, although serious local and systemic complications are still possible.⁷⁻¹²

For maximal aesthetic benefit to be achieved following any of these techniques, overall trauma to the tissue should be minimized and skin retraction maximized. Adipose tissue itself consists of globules of fat encapsulated within a matrix of loose collagen fibers, or septae, which also house and protect the nervous and vascular network. The trauma associated with various liposuction procedures damages this lattice to some degree, which translates into damage to the nerves and blood vessels nourishing the local tissue. It therefore stands to reason that sparing septal fibers during liposuction will lead to less associated bleeding and postprocedure ecchymosis, as well as reduced

Received for publication February 26, 2010.

From the S-thetic Clinic Düsseldorf, Düsseldorf, Germany.

Corresponding author: Afschin Fatemi, MD, S-thetic Clinic Düsseldorf, Kaiserswerther Markt 25, Düsseldorf, Germany 40489 (e-mail: info@s-thetic.de).

recovery time. The fibrous septae network of the adipose tissue is also attached to the dermis and to deeper structures. Because of this attachment, its preservation may be a key factor in maximizing skin retraction after liposuction.

In this study, we investigated which of the current liposuction techniques was associated with the greatest degree of septal fiber preservation. Septal fiber preservation may serve as a marker for the relative trauma of a given technique and also may be predictive of potential skin retraction benefits. The range of liposuction techniques we performed included standard manual suction-assisted liposuction (SAL), power-assisted liposuction (PAL), power water-assisted liposuction (WAL), ultrasound-assisted liposuction (UAL), and laser-assisted liposuction (LAL).

SAL is the manual reciprocation of a cannula that uses shear forces to perforate fatty tissue for removal by suction.¹³ PAL is a similar technique using a mechanically driven vibrating and reciprocating cannula with reported benefits over traditional SAL including reduced operator fatigue.^{14–16} Both techniques are associated with trauma to local tissue; however, PAL is considered to be less traumatic.¹⁶

WAL employs a high-pressure water jet to gently disrupt and dislodge fatty tissue during liposuction. In a prospective study comparing postoperative pain and ecchymosis in WAL versus SAL, statistically reduced rates of both side effects were correlated with WAL.¹⁷ Study authors concluded that these results served as proof that WAL was less traumatic to the vessels and nerves coursing through the adipose tissue.¹⁷ UAL involves the introduction of ultrasonic energy into adipose tissue, which emulsifies the fat and provides easier and gentler suction.¹⁸ In 2000, Scuderi et al¹⁹ conducted a comparative survey and identified UAL and PAL as resulting in reduced vascular injury compared with SAL.

LAL, the newest technique, involves the introduction of laser energy through a cannula or by delivering laser energy via a quartz treatment tip without a cannula to disrupt adipose tissue and emulsify fat for easier suction. The LAL system we used employs the selective wavelengths of 924 nm for adipose tissue and 975 nm for water-rich tissue.²⁰ Seckel et al²⁰ recently demonstrated that these wavelengths enable larger laser tunnels with minimal risk of dermal burns and theorized that heating of the collagen in septal fibers may induce skin retraction. Clinical benefits of this device were investigated by Weiss and Beasley,²¹ who observed significant fat reduction with minimal

downtime, tighter skin, and high rates of patient satisfaction.

The purpose of these pilot studies was to use gross dissection and in vivo endoscopy to qualitatively and quantitatively compare the number of intact septal fibers following 924/975-nm LAL, PAL, SAL, UAL, and WAL performed in abdominoplasty and liposuction patients and cadavers. All treatments were performed at the S-thetic Clinic Düsseldorf (Düsseldorf, Germany), a multidisciplinary clinical setting offering a wide range of surgical and nonsurgical aesthetic procedures.

Methods

Devices/Settings

WAL treatments were performed using the Body-Jet system (Human Med, Schwerin, Germany) at flow settings of “2” with a 4.7-mm aspiration cannula. UAL treatments were performed using the Sonoca 180 (Söring Inc, North Richland Hills, Tex) at settings of 60 kHz with a 4.2-mm cannula. The Vibrasat Power-Assisted Cannula (Moeller Medical Inc, Fulda, Germany) was used to perform PAL treatments along with a 4-mm aspiration cannula. LAL treatments were performed using a 924/975-nm diode laser system (Aspire platform with SlimLipo laser module, Palomar Medical Technologies Inc, Burlington, Mass). SAL treatments were performed using a 24-hole Sattler cannula (European Aesthetics Inc, Munich, Germany) and a 4-mm aspiration cannula.

Study Groups

ABDOMINOPLASTY WITH LIPOSUCTION PATIENTS

Prior to performing the procedure, the treating physician carefully examined and evaluated each patient for existing contraindications, including liposuction. Each patient was counseled with regard to the anticipated treatment results and the potential for complications during and following treatment. The 52 patients undergoing abdominoplasty were healthy adults who expressed the wish to undergo elective abdominoplasty in the years 2003–2009. During this time period, split-body treatments comparing the various liposuction techniques were performed with different liposuction cannulas under general anesthesia prior to excision of excess adipose and skin tissue. Following infiltration of tumescent fluid, excess skin under the umbilicus was treated with 2 or 3 of the following liposuction techniques: 924/975-nm LAL, PAL, SAL, UAL, or WAL (see Table 1). Cannulas with similarly sized diameters were used for all techniques to ensure consistency of treatments. Surrounding tissue not removed as part of the abdominoplasty

Table 1. Number of Subjects per Study Group Receiving Various Split-Body Treatments*

Subject Group	WAL Only	SAL vs PAL	SAL vs UAL	SAL vs WAL	SAL vs LAL	PAL vs LAL	PAL vs UAL	PAL vs WAL	SAL vs PAL vs WAL	SAL vs PAL vs WAL	SAL vs PAL vs LAL
Abdominoplasty (n = 52)	1	10	5	5	9	9	4	4	2	1	2
Cadavers (n = 12)	0	3	2	3	3	1	0	0	0	0	0
Liposuction (n = 32)	0	3	3	5	4	12	2	3	0	0	0

*LAL indicates laser-assisted liposuction; PAL, power-assisted liposuction; SAL, suction-assisted liposuction; UAL, ultrasound-assisted liposuction; WAL, water-assisted liposuction.

procedure was sculpted for fat reduction. Treated umbilical tissue was dissected, enabling in vivo endoscopic observations of intact septal fibers. For standardized endoscopic imaging of intact septal fibers after each procedure, the endoscope was introduced approximately 5 cm into the incision site, retracted 1 cm, and an image was captured. These images were used to tabulate the number of intact septal fibers remaining after a given technique and to compare the relative trauma of split-body treatments using different liposuction methods.

CADAVERS

Twelve abdominal regions of fresh frozen cadavers were treated with 2 different liposuction techniques each, such as 924/975-nm LAL, PAL, SAL, UAL, or WAL. Tissue underwent standard liposuction with 1 of these 5 techniques and was then dissected and examined for gross pathology. Septal fiber preservation was qualitatively judged using a 3-point scale (0 = approximately same amount of fibers, 1 = more fibers, 2 = significantly more fibers).

LIPOSUCTION PATIENTS

Thirty-two patients over the past 6 years underwent tumescent liposuction using 924/975-nm LAL, PAL, SAL, UAL, or WAL followed by the endoscopic imaging procedure and septal fiber count tabulation as described previously.

Results

Cadaver Group Data

Qualitative observations of treated cadaver tissue demonstrated that PAL, SAL, and LAL treatments were all associated with increased preservation of septal fibers as compared with UAL or WAL. In particular, when compared with WAL, both SAL and PAL resulted in significantly increased numbers of

fibers. Split-body comparisons between PAL and SAL revealed increased numbers of PAL fibers and LAL treatments resulted in significantly increased numbers of fibers as compared with SAL (Table 2).

Abdominoplasty Group and In Vivo Liposuction Data

Gross pathology from abdominoplasty tissue samples revealed well-defined impact zones enabling qualitative comparisons of the number of intact septal fibers left after each technique. Representative endoscopic images for each technique are shown in Figure 1.

Table 2. Qualitative Grading of Septal Fiber Preservation Following Split-Body Treatment in 12 Cadavers*

Type of Split-Body Treatment	Rank Order	Septal Fiber Score (n = Cases With Score)		
		"0"	"1"	"2"
SAL vs PAL (n = 3)	SAL < PAL	0	3	0
SAL vs UAL (n = 2)	SAL > UAL	1	1	0
SAL vs WAL (n = 2)	SAL > WAL	0	1	1
SAL vs LAL (n = 3)	SAL < LAL	0	1	2
PAL vs LAL (n = 1)	PAL > LAL	0	1	0
PAL vs WAL (n = 1)	PAL > WAL	0	0	1

*Septal fiber score was assigned following review of each treated area for comparison of intact septal fibers on one treated side versus the other. Score key: 0 = approximately same number of fibers; 1 = more fibers; 2 = significantly more fibers. LAL indicates laser-assisted liposuction; PAL, power-assisted liposuction; SAL, suction-assisted liposuction; UAL, ultrasound-assisted liposuction; WAL, water-assisted liposuction.

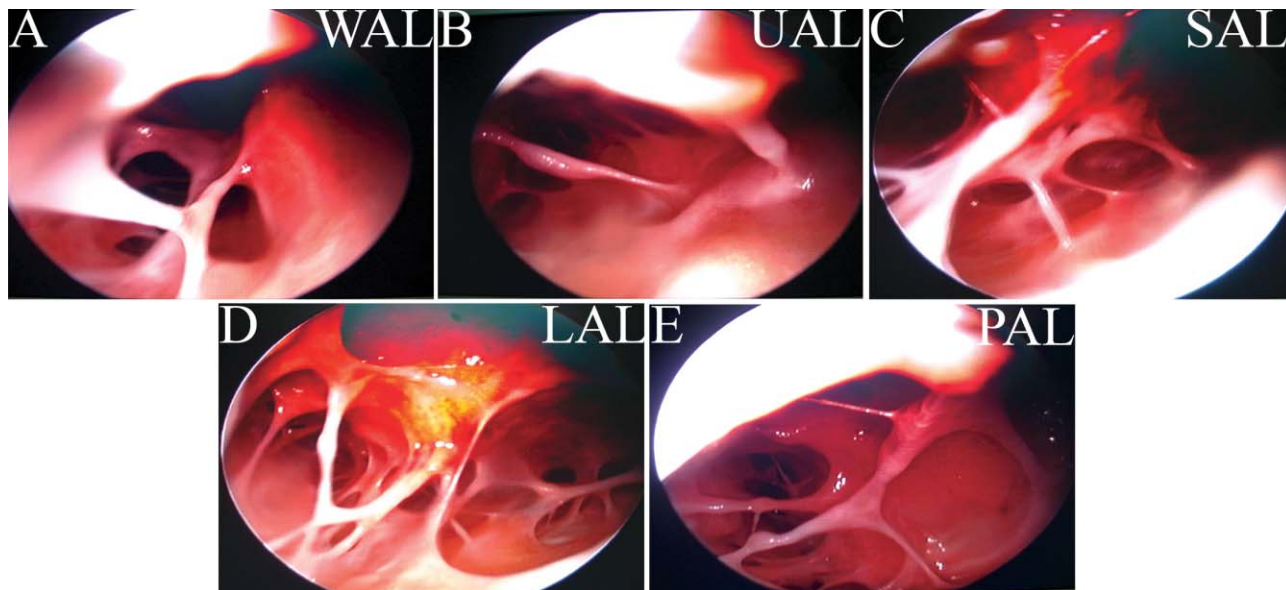


Figure 1. Representative *in vivo* endoscopic images following various liposuction procedures. (A) The greatest disruption of septal fibers was observed following water-assisted liposuction (WAL). Less disruption was observed following (B) ultrasound-assisted liposuction (UAL) and (C) suction-assisted liposuction (SAL). (D–E) The greatest preservation of septal fibers was observed following laser-assisted liposuction (LAL) and power-assisted liposuction (PAL).

Initial examinations revealed that WAL resulted in the greatest disruption of septal fibers, followed by UAL, SAL, PAL, and LAL, with the latter 2 techniques leaving comparable numbers of intact fibers (Figure 1A–E).

Real-time endoscopic quantification of preserved septal fibers in the liposuction and abdominoplasty groups further confirmed the trend observed in the cadaver group. For most comparisons, the numbers of observations were too low in the liposuction group ($n = 2\text{--}4$) to warrant separate analysis of endoscopic results collected in the liposuction group versus the abdominoplasty group, with the exception of PAL versus LAL, for which the numbers were significant ($n = 12$ for LAL, $n = 11$ for PAL). Separate analyses of these cases revealed that equivalent results were obtained in both study groups, supporting pooling of the data from the 2 groups. The mean number of intact septal fibers left after LAL treatments in either the liposuction or abdominoplasty group ($n = 36$ total) was 18 ± 4 (SD), compared with a mean of 17 ± 4 (SD) following PAL treatments ($n = 53$ total). SAL treatments ($n = 49$ total) were associated with a mean of 12 ± 3 (SD) fibers, compared with a mean of 9 ± 4 (SD) following UAL treatments ($n = 15$ total). The lowest number of intact fibers was observed following WAL treatments ($n = 19$ total), with a mean of 6 ± 3 (SD; Figure 2).

Comparisons between the numbers of intact septal fibers left after each technique performed in split-body

treatments revealed statistically significant differences between the different liposuction methods except between PAL and LAL, which were essentially equivalent (mean difference 0.2 ± 3.4 ; data not shown). PAL had significantly more septal fibers present after the procedure than all of the other methods ($P < .001$), except for LAL. SAL had more fibers present than either UAL or WAL ($P < .001$). LAL had more fibers present after treatment than SAL ($P < .001$). In sum, the rank order for the 5 liposuction methods tested was PAL = LAL > SAL > UAL > WAL.

Aspirate Analysis

Results from the aspirate analysis correlated with procedure trauma results; aspirates of PAL and 924/975-nm LAL were yellow compared with the reddish aspirate of WAL, suggesting that more extensive vessel corruption and subsequent hemoglobin leakage occurred with the latter procedure. Blood loss following either UAL or SAL procedures fell somewhere in between these groups. Microscopy studies of the aspirate analysis revealed greater disruption of the adipocyte cell membrane following 924-nm LAL as compared with all the other techniques.

Safety

There were no severe complications observed (infection, embolism, organ perforation, etc) in either

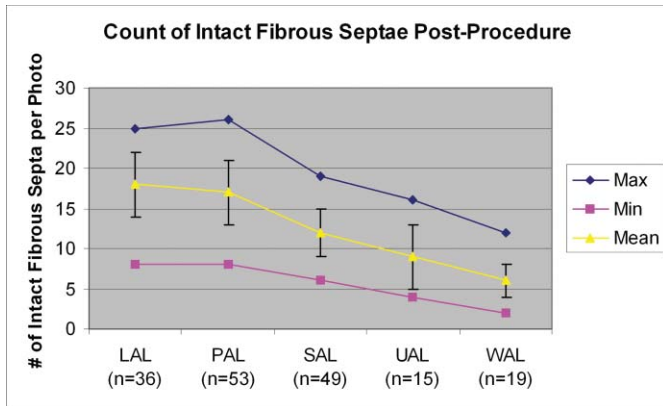


Figure 2. Count of intact fibrous septa after treatment. Blue line indicates the maximum numbers of septal fibers preserved following each technique, yellow line indicates the mean numbers of septal fibers, and pink line indicates the minimum numbers of septal fibers. Values for the maximum numbers of fibers were as follows: 25 fibers with laser-assisted liposuction (LAL), 26 fibers with power-assisted liposuction (PAL), 19 fibers with suction-assisted liposuction (SAL), 16 fibers with ultrasound-assisted liposuction (UAL), and 12 fibers with water-assisted liposuction (WAL). Values for the mean numbers of fibers were as follows: 18 fibers with LAL, 17 fibers with PAL, 12 fibers with SAL, 9 fibers with UAL, and 6 fibers with WAL. Values for the minimum numbers of fibers were as follows: 8 fibers with LAL and PAL, 6 fibers with SAL, 4 fibers with UAL, and 2 fibers with WAL. Error bars indicate \pm standard deviation for the mean number of fibers.

the abdominoplasty or liposuction groups. Observed adverse events were transient and limited to those commonly expected such as edema, ecchymosis, numbness, and tenderness. Swelling and fibrosis were observed in a small number of cases.

Discussion

Liposuction methods that reduce the amount of trauma from surgery have value to patients because of the potential improvements in the quality and speed of recovery as well as the reduced likelihood of complications. While large, prospective, well-controlled clinical studies remain the most valid means to compare surgical procedures, these studies are economically impractical in the field of liposuction. Small-scale, within-patient comparisons between 2 methods are often used, but limitations of these studies include increased risks of asymmetrical outcome and the subsequent challenges of revisional corrections. Comparison across multiple methods is clinically even more challenging. For these reasons, we chose to perform real-time observation of adipose tissue immediately

following 5 different liposuction techniques to directly compare the relative trauma of each procedure. The ideal liposuction technique effectively removes fat with minimal trauma to the septal structures of the adipose tissue. Therefore, counting the number of intact septal fibers after each procedure is a reasonable means to compare the relative trauma between these methods. The liposuction techniques that leave the greatest numbers of intact septal fibers are less traumatic to the tissue and have the potential to improve the quality and speed of recovery as well as reduce the risks of complications.

For this report, tumesced tissue from abdominoplasty or liposuction patients and fresh cadavers was treated with various liposuction techniques, and septal fiber preservation was evaluated both qualitatively and quantitatively. The abdominoplasty group served as a pilot program to test the feasibility of using in vivo endoscopy to quantify intact septal fibers remaining after various liposuction techniques. The size of cannula and the technique were controlled in the best efforts possible for each method.

Overall, PAL and 924/975-nm LAL procedures left the highest number of intact septal fibers, suggesting that these techniques were the least traumatic. Consistency across all of the observational methods, including the aspirate analysis, was high. Reduced trauma with PAL may stem from the fact that it uses a cannula that vibrates and reciprocates through the tissue as opposed to the blunt mechanical damage that occurs with SAL. Reduced trauma with 924/975-nm LAL may be attributed to continuous-wave mode delivery, inclusion of selective wavelengths for fat (924 nm) and hydrated tissue (975 nm), and cannulas with a smaller diameter (1.5 mm). In comparison, UAL uses cannulas of a much larger diameter (approximately 4–6 mm), and the back and forth motion of the “hot tip,” as opposed to pushing the tissue aside, may cause greater disruption of the fibers. Regarding the highest trauma observed in WAL-treated tissue, we speculate this may be due to the use of a high-pressure (setting flow at 2) water spray, which is nonselective in its damage of adipose tissue.

The connective tissue that separates adipose tissue into lobules is composed of fibrous septa that protect the nerve and blood supply of the tissue. Protection of the fibrous septa will result in better preservation of the neural and vascular supply that innervate and nourish the tissue, resulting in faster healing and reduced risk of necrosis, bruising, swelling, or paresthesia-like symptoms (numbness, tingling). Protection of the lymphatic capillaries within this tissue also aids in

posttreatment recovery through its solicitation of the immune response. Septal fibers also serve as structural attachments between the adipose tissue and the dermis, such that, theoretically, thermally induced retraction of these fibers may manifest in retraction of overlying dermis. The mechanism of action for this outcome is controlled thermal coagulation of the collagen and elastin-containing fibers to induce neocollagenesis and neoelastogenesis.

Summary and Conclusion

Direct observations of adipose tissue following PAL, SAL, 924/975-nm LAL, UAL, and WAL showed that 924/975-nm LAL and PAL were equally associated with the greatest preservation of septal fibers after treatment in comparison with all of the other methods. SAL was observed to have more septal fibers than either UAL or WAL. These direct observations indicate that the adipose tissue suffers less trauma during removal of fat using either PAL or LAL, and these differences have the potential to translate into an improved and faster recovery as well as a decreased risk of complications. Findings suggest the merit of further investigation into how these different techniques correlate with clinical recovery, safety, and aesthetic outcomes.

References

1. van der Lugt C, Romero C, Ancona D, Al-Zarouni M, Perera J, Trelles MA. A multicenter study of cellulite treatment with a variable emission radio frequency system. *Dermatol Ther.* 2009;22:74–84.
2. Nootheti PK, Magpantay A, Yosowitz G, Calderon S, Goldman MP. A single center, randomized, comparative, prospective clinical study to determine the efficacy of the VelaSmooth system versus the Triactive system for the treatment of cellulite. *Lasers Surg Med.* 2006;38:908–912.
3. Kulick M. Evaluation of a combined laser-radio frequency device (Polaris WR) for the nonablative treatment of facial wrinkles. *J Cosmet Laser Ther.* 2005;7(2):87–92.
4. Sadick N, Magro C. A study evaluating the safety and efficacy of the VelaSmooth system in the treatment of cellulite. *J Cosmet Laser Ther.* 2007;9(1):15–20.
5. Romero C, Caballero N, Herrero M, Ruiz R, Sadick NS, Trelles MA. Effects of cellulite treatment with RF, IR light, mechanical massage and suction treating one buttock with the contralateral as a control. *J Cosmet Laser Ther.* 2008;10(4):193–201.
6. Grazer FM, de Jong RH. Fatal outcomes from liposuction: census survey of cosmetic surgeons. *Plast Reconstr Surg.* 2000;105:436–446.
7. Hanke CW, Bernstein G, Bullock S. Safety of tumescent liposuction in 15,336 patients: national survey results. *Dermatol Surg.* 1995;21:459–462.
8. Fatemi A. Liposuktion in TLA—ein risikofreies Verfahren? *Hauptsache Haut.* 2000;4:42–43.
9. Fatemi A, Schulte K, Bohmer J. Tumescent local anesthesia. *Z Asth Op Derm.* 2001;2(3):44–45.
10. Fatemi A. Tumescent local anesthesia. In: Shiffman MA, Di Giuseppe A, eds. *Liposuction: Principles and Practice.* Berlin, Germany: Springer; 2006:80–84.
11. Lehnhardt M, Homann HH, Daigeler A, Hauser J, Palka P, Steinau HU. Major and lethal complications of liposuction: a review of 72 cases in Germany between 1998 and 2002. *Plast Reconstr Surg.* 2008;121:396e–403e.
12. Katz B, McBean J. Laser-assisted lipolysis: a report on complications. *J Cosmet Laser Ther.* 2008;10:231–233.
13. Fischer G. Liposculpture: the “correct” history of liposuction. Part I. *J Dermatol Surg Oncol.* 1990;16:1087–1089.
14. Coleman WP III. The history of liposuction and fat transplantation in America. *Dermatol Clin.* 1999;17:723–727.
15. Coleman WP III. Powered liposuction. *Dermatol Surg.* 2000;26:315–318.
16. Katz BE, Bruck MC, Coleman WP III. The benefits of powered liposuction versus traditional liposuction: a paired comparison analysis. *Dermatol Surg.* 2001;27:863–867.
17. Araco A, Gravante G, Araco F, Delogu D, Cervelli V. Comparison of power water-assisted and traditional liposuction: a prospective randomized trial of postoperative pain. *Aesthetic Plast Surg.* 2007;31:259–265.
18. Silberg BN. The technique of external ultrasound-assisted lipoplasty. *Plast Reconstr Surg.* 1998;101:552.
19. Scuderi N, Paolini G, Grippaudo FR, Tenna S. Comparative evaluation of traditional, ultrasonic, and pneumatic assisted lipoplasty: analysis of local and systemic effects, efficacy, and costs of these methods. *Aesthetic Plast Surg.* 2000;24:395–400.
20. Seckel BR, Doherty ST, Childs JJ, Smirnov MZ, Cohen RH, Altshuler GB. The role of laser tunnels in laser-assisted lipolysis. *Lasers Surg Med.* 2009;41:728–737.
21. Weiss RA, Beasley K. Laser-assisted liposuction using a novel blend of lipid- and water-selective wavelengths. *Lasers Surg Med.* 2009;41:760–766.